



Case Report

Tuberculosis of the breast: A case report in a tertiary health institution, South-South Nigeria

Theophilus Ipeh Ugbeni¹, Abiola Grace Adekanye², Joseph Essien Udosen³, Samuel Akpan⁴

Departments of ¹Pathology, ²Otorhinolaryngology and ³Surgery, University of Calabar, ⁴Department of Surgery, University of Calabar Teaching Hospital, Calabar, Cross River State, Nigeria.



*Corresponding author

Abiola Grace Adekanye,
Department of
Otorhinolaryngology,
University of Calabar, Calabar,
Cross River State, Nigeria.

abiolaadekanye@gmail.com

Received: 03 September 2021
Accepted: 07 November 2022
EPub Ahead of Print: 21 March 2023
Published:

DOI
10.25259/CJHS_40_2021

Quick Response Code:



ABSTRACT

Tuberculosis (TB) of the breast is a rare disease that typically affects women of reproductive age, mainly between 15 and 25 years of age. TB of the breast has a non-specific clinical presentation and may present as a breast lump, abscess, or sinus, and it may sometimes mimic breast cancer. Histological diagnosis is necessary to avoid mismanagement of potentially curable breast disease. We present a case of an 18-year-old female with a left upper quadrant breast lump of 1-year duration. The fine-needle aspiration cytology of the breast lump was negative for malignancy. However, histological diagnosis of the excised breast lump confirmed TB of the breast.

Keywords: Tuberculosis, Fibroadenoma, Female, Breast neoplasms, Diagnostic error

INTRODUCTION

Breast tuberculosis (TB) is a rare disease with a reported incidence of <0.1% of all breast lesions in Western countries.^[1] The incidence in TB-endemic regions such as India and Africa is between 3% and 4%. Breast TB has a multifaceted presentation, and it is, therefore, labeled as a “great masquerade.”^[2] The clinical presentation of breast TB is often insidious and non-specific, mimicking the signs of breast carcinoma.^[1] The disease affects women of reproductive age between the ages of 21 and 30 years and can present as a breast abscess, a one-sided painless breast mass,^[3] or sinus, and it may sometimes mimic breast cancer.^[4] A high index of suspicion, a search for risk factors, and a histological diagnosis are necessary tools in its diagnosis to avoid mismanagement of potentially curable breast disease.^[5] Histopathological examinations are more important than bacteriological examinations to confirm a diagnosis of breast TB.^[6] Furthermore, fine-needle aspiration cytology (FNAC) proved in the diagnosis of breast TB, thereby preventing unwarranted surgical removal.^[7] The incidence of breast TB in Nigeria is unknown due to the paucity of information.^[8] Hence, breast TB should be a breast lump differential in endemic regions like Nigeria.

We present a case of an 18-year-old female with a left upper quadrant breast lump of 1-year duration. The FNAC of the breast lump was negative for malignancy. In addition, the excision of the breast lump was done, and a histological diagnosis confirmed granulomatous mastitis consistent with breast TB. The post-surgical period was uneventful and she was referred to the endemic disease unit for further management.

This is an open-access article distributed under the terms of the Creative Commons Attribution-Non Commercial-Share Alike 4.0 License, which allows others to remix, transform, and build upon the work non-commercially, as long as the author is credited and the new creations are licensed under the identical terms.

©2023 Published by Scientific Scholar on behalf of Calabar Journal of Health Sciences

CASE REPORT

We report an 18-year-old teenage girl who presented with 12 months history of a lump in her left breast with intermittent pains. She had no history of swelling on the other part of her body and nil history of contraception nor a family history of breast cancer. There was no associated nipple discharge, breathlessness, or drenching night sweats. However, there was associated progressive weight loss. A provisional diagnosis of fibroadenoma to rule out malignancy was made. She underwent a fine-needle aspiration, which was negative for malignancy. Furthermore, an excisional biopsy was done and sent for a histopathology examination.

Histopathologic findings were: Macroscopically, the specimen consisted of multiple irregularly shaped breast masses with an aggregate weight of 50 g. The largest mass measures 4.0 cm × 3.0 cm × 1.5 cm, and the smallest mass was 1.0 cm × 0.9 cm × 0.5 cm. Their external surfaces were smooth and shiny and cut surfaces were friable with a creamy color to yellowish appearance. The microscopic features of breast TB are revealed in [Figure 1a-e]. The histologic sections revealed numerous granulomas consisting of mononuclear inflammatory cells, epithelioid cells, areas of caseous necrosis, and giant cells of Langhans, which were in keeping with tuberculous granuloma.

She was referred to the endemic disease unit for antituberculous medication and treatment. She recovered fully without complications and was discharged home with contact tracing done. Breast TB should be an important differential diagnosis of fibroadenoma of the breast.

DISCUSSION

Globally, tuberculous mastitis is rare and uncommon even in regions where TB is endemic and essentially poses a diagnostic challenge as it usually masquerades as carcinoma or other

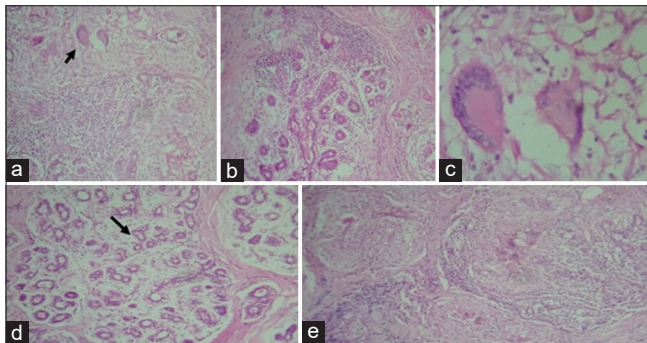


Figure 1(a-e): Photomicrograph of breast tissue stained with routine hematoxylin and Eosin showing granulomas consisting of epithelioid-like cells, mononuclear inflammatory cells, and giant cells of the Langhan types and areas of caseous necrosis. The arrows in figure 1a; Langhan giant cells. (b) Periductal Inflammation, (c) giant cells of Langhan type, (d) proliferating breast ducts, (e) granulomas and areas of caseous necrosis.

primary diseases of the breast.^[3] FNAC is the most commonly used diagnostic method representing 32%, followed closely by biopsy (27%), Ziehl–Neelsen stain for acid-fast bacillus (26%), culture (13%), and polymerase chain reaction (2%).^[7] Primary breast TB arises through openings or abrasions of the nipple ducts. The more common secondary form spreads through lymphatic, hematogenic, or adjoining seeding from the ribs, pleural space, or rectus sheath on an intra-abdominal basis.^[9] Quaglio *et al.*, in their study of 1478 cases of TB breast, showed that 19% of the women had a previous history of breast TB and the most common clinical appearance of the lesion was breast lump (75%) with associated findings of axillary lymphadenitis (33%) followed by sinus or fistula (24%), while the most common symptoms include fever and pain, which reported in 42% and 28% of cases, respectively. A tissue biopsy is essential for confirmatory diagnosis, also to rule out any coexisting malignancy.^[10]

In the index case, the patient presented with a breast mass with intermittent pain and slight weight loss. However, there was no palpable axillary mass. The aspiration cytology report was negative for malignancy but not conclusive of breast TB. An excisional biopsy of the breast lump was done, and the histologic appearance was that of TB of the breast.

CONCLUSION

Breast TB must always be a differential diagnosis of breast abscess, lump, or fistula with poor response to empiric antibiotic treatment, especially in TB-endemic regions like Nigeria. Histopathologic evaluation is necessary for the diagnosis of breast TB. We recommend that private practitioners, family physicians, and general surgeons send all excised breast lump tissue removed from all patients, irrespective of age, for histopathologic studies for appropriate and definitive diagnosis to prevent diagnostic error and unnecessary mastectomy in potentially curable breast disease.

Acknowledgment

The authors acknowledged all other health workers that took part in the management of the patient.

Declaration of patient consent

The authors confirm that they have obtained all appropriate patient consent.

Financial support and sponsorship

Nil.

Conflicts of interest

There are no conflicts of interest.

REFERENCES

1. Marinopoulos S, Lourabou D, Gatzionis T, Dimitrakakis C, Papaspyrou I, Antsaklis A. Breast tuberculosis: Diagnosis, management, and treatment. *Int J Surg Case Rep* 2012;3:548-50.
2. Gon S, Bhattacharyya A, Majumdar B, Kundu S. Tubercular mastitis-a great masquerader. *Turk Patoloji Derg* 2013;29:61-3.
3. Mathur R, Vatiliya M, Chitimilla S. Tuberculosis of breast: A case report. *West Lond Med J* 2009;1:37-43.
4. Al-Roomi E, Jamal W, Al-Mosawi A, Rotimi VO. Mycobacterium tuberculosis breast infection mimicking pyogenic abscesses in Kuwait. *Med Princ Pract* 2009;18:245-7.
5. Dodiya-Manuel ST, Dodiya-Manuel A. Tuberculosis of the breast. *Niger J Med* 2013;22:72-4.
6. Al-Mari MR, Aref E, Omar AJ. Mammographic features of isolated tuberculosis mastitis. *Saudi Med J* 2005;26:646-50.
7. Qualio G, Pizzol D, Isaakidis P, Bortolani A, Tognon F, Marotta C, *et al.* Breast tuberculosis in women: A systematic review. *Am J Trop Med Hyg* 2019;101:12-21.
8. Sabageh D, Amao EA, Ayo-Aderibigbe AA, Sabageh AO. Tuberculous mastitis simulating carcinoma of the breast in a young Nigeria woman: A case report. *Pan Afr Med J* 2015;21:125.
9. Baharoon S. Tuberculosis of the breast. *Ann Thorac Med* 2008;3:110-4.
10. Tauro LF, Martis JS, George C, Kamath A, Lobo G, Hegde BR. Tuberculous mastitis presenting as breast abscess. *Oman Med J* 2011;26:53-5.

How to cite this article: Ugbem TI, Adekanye AG, Udosen JE, Akpan S. Tuberculosis of the breast: A case report in a tertiary health institution, South-South Nigeria. *Calabar J Health Sci*, doi: 10.25259/CJHS_40_2021