




Case Report

Adjunctive orthodontic management of a missing upper right central incisor in a 12-year-old male using a fixed orthodontic appliance

Monica Ndudi Adekoya

Department of Child Dental Health, Faculty of Dentistry, College of Medical Sciences, University of Calabar, Calabar, Cross River State, Nigeria.



*Corresponding author:

Monica Ndudi Adekoya,
Department of Child Dental
Health, Faculty of Dentistry,
College of Medical Sciences,
University of Calabar, Calabar,
Cross River State, Nigeria.

moniks4life@yahoo.com

Received : 05 September 2020

Accepted : 10 April 2021

Published : 30 June 2021

DOI

10.25259/CJHS_39_2020

Quick Response Code:



ABSTRACT

This article presents a successful orthodontic management of a 12-year-old male using a fixed orthodontic appliance (straight wire technique). His orthodontic treatment was hinged on creating enough space to accept an artificial tooth, correcting the horizontal and vertical relationships of the upper incisors to the lower and the midline shift. Ultimately, an esthetic smile was achieved; function and self-esteem were improved when the artificial tooth was finally fixed.

Keywords: Adjunctive, Missing tooth, Aesthetics, Fixed orthodontic appliance

INTRODUCTION

The demand for orthodontic treatment by individuals with cases of missing anterior teeth is very high because of the obvious impact this condition has on both dental and facial esthetics.^[1,2] Dental trauma comprises 5% of injuries among children and adolescents, of this, avulsion is about 0.5–3%.^[3]

The upper central incisors are the most commonly affected by trauma. Furthermore, such trauma has been related to increased overjet, (horizontal relationship of the upper incisor to the lower), which is a complication of malocclusion. The injury frequency increases as the overjet increases in individuals.^[4] Other causes of tooth loss are dental decay, gingival, and periodontal disease.^[5,6] The periodontium comprises periodontal ligament, cementum, alveolar bone, and the gingiva (the soft-tissue component), diseases affecting the gingival tissues can progress to affect the whole periodontium if not treated.^[5] This condition can be enhanced by chronic mouth breathing due to nasal adenoids.^[6] Dry mouth due to some medications or menopause can also predispose one to dental caries and periodontitis. Smokers have a 3 times greater risk of developing gingival disease more than non-smokers.^[7]

Loss of a single tooth can cause adjacent teeth to drift toward the space; this can affect function (chewing/mastication) and also difficulty in keeping good oral hygiene.^[8,9] Bone resorption also occurs with loss of teeth and the longer it takes to replace, the more the space loss and bone resorption.^[9]

This is an open-access article distributed under the terms of the Creative Commons Attribution-Non Commercial-Share Alike 4.0 License, which allows others to remix, tweak, and build upon the work non-commercially, as long as the author is credited and the new creations are licensed under the identical terms.

©2021 Published by Scientific Scholar on behalf of Calabar Journal of Health Sciences

CASE REPORT

The patient was a 12-year-old male who presented with the complaints of a missing tooth, due to trauma of about 2½ years, and unpleasant space, not enough to accept an artificial tooth. His medical history was not contributory but had a positive dental history.

Extraoral examination revealed a face which appeared normal with no asymmetry or scarifications but had a slight dishing/collapse on the right side of the upper lip, just around the area of the missing tooth [Figure 1].

Intraoral examination showed a missing upper right central incisor, drifted upper right lateral, and left central incisor reducing the space of the missing tooth. There were rotations of the lower anterior teeth, causing mild crowding of the lower anterior segment. The anteroposterior view revealed increased overjet of 5.5 mm and a deep/increased overbite of about 4.5 mm as against the normal range of 2–4 mm.^[10] The patient produced a lisp sound when asked to pronounce words such as “The” and “Is” due to escape of air from the space left by the missing tooth.^[11,12] There was a shift of the upper midline to the right, this was as a result of the drifting of the adjacent teeth into the space.

Treatment objectives

The treatment objectives for this patient were as follows:

1. To create space enough for a prosthetic tooth replacement.
2. To correct the overjet, the overbite, and the upper midline shift.

3. To unravel the mild crowding in the anterior segment of the lower arch.
4. To achieve an esthetic smile, function, and clear speech.

Treatment alternatives

There were three alternatives:

1. The first alternative was the use of a removable upper arch expander to create the needed space, but this would not have addressed the mild crowding in the lower arch, the overjet, overbite, and the midline shift.
2. The second was to move the lateral incisor and the canine to the spaces of the central and lateral, respectively, using a fixed orthodontic appliance, then crown lateral incisor to look like the central and trim the canine (crown conversion) to look like the lateral incisor. This procedure is really cumbersome and more expensive. The question here was where to transfer the remaining space and esthetics might be questionable.
3. The third alternative was to create space enough for a prosthetic tooth replacement simply using fixed orthodontic appliance, and at the same time correct other anomalies, like the overjet, overbite, upper midline shift, and the mild crowding in the lower arch.

Treatment progress

Treatment commenced on April 11, 2018. The appliance was fixed, and an open coil spring was incorporated into the wire, after some months, to gradually create the needed space

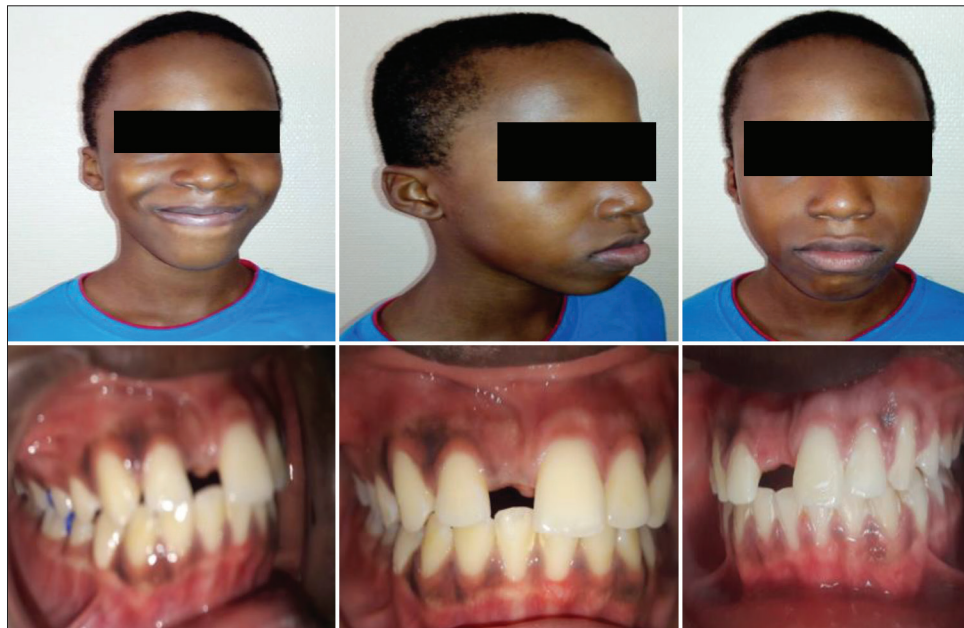

Figure 1: Before treatment.

[Figure 2]. The stainless steel arch wires were adjusted for arch expansion, also resulting in space creation. Orthodontic appointments were scheduled every 6–7 weeks.

About 45 weeks into treatment, a stock tooth was incorporated after enough space had been created. Finishing stage was completed at about 64 weeks, and the arch wires were left in place for few more weeks.

TREATMENT RESULT

At the end of the treatment, Class I canine and molar relationships were maintained. Enough space was created and a removable retainer with a stock tooth was fitted satisfactorily. The overjet, overbite, and the midline shift were all corrected. The crowding in the anterior segment of the lower arch was unraveled. Esthetics was achieved as well as function.

DISCUSSION

It is apparent that people cannot enjoy complete social and mental well-being if their mouths are esthetically displeasing.^[13] The loss of anterior teeth has serious functional, esthetic disabilities in addition to compromising the patient's quality of life.^[1,6] As regard functional disability, Runte *et al.*^[12] in their study found that the tongue comes into contact with the teeth, alveolar ridge, or hard palate during articulation of speech sounds. Absence of teeth may cause a changed perception and may alter tongue movement or position which is helpful in the production of speech.^[11]

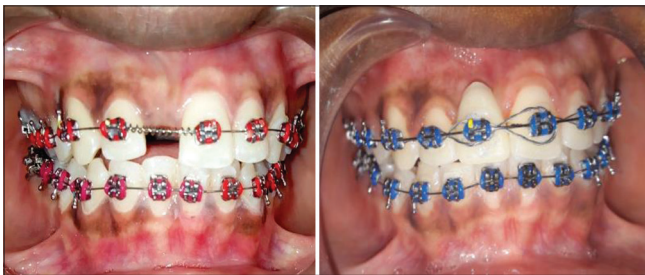

Figure 2: During treatment.

An important factor in the successful treatment of this malocclusion was the age of the patient. Schubert *et al.*^[14] reported that older patients are less responsive to orthodontic force in comparison to younger patients. Patient's compliance with appointments, not breaking any brackets, and keeping to all instructions were crucial for success. The uprighting of the upper left central incisor done by right bracket positioning, and the expansion of the upper arch wire, and also, the effect of the coil spring incorporated into the arch wire resulted in space creation.^[15] The mild crowding in the anterior segment of the lower arch was corrected by slight expansion of the arch. Expanding the arch wire, expands the dental arch, creating the space needed for the teeth to align properly. The intrusion of the anterior and extrusion of the posterior segments of both arches corrected the vertical dimension of the arches.

The major advantages of this treatment options are (1) eliminating the tendency of future reopening of the anterior space, which occurs more with the option of closing the space orthodontically. The second advantage is the total avoidance of enameloplasty, the trimming off of enamel, which occurs during crown conversions of the upper right canine and first premolar to resemble the teeth they substitute, in the second option. Third, there is a better option of tooth color to match the remaining anterior teeth during the prosthetic replacement. This is difficult with the second option, because canine substituting for an incisor tooth can cause an esthetic problem. Closing of a unilateral space will pose a challenge of imbalance compared with closing a bilateral space. On the other hand, the treatment used in this case report gives a lifelong use of prosthetic restorations, which could lead to high cost in the long run.^[1,16,17,18]

Retaining or maintaining the teeth in their new but correct positions is very necessary and plays an important role in preventing relapse. This is achieved by both removable and fixed appliances. Hawley's retainer with an incorporated stock tooth was fitted for this patient pending when the patient could get a more definitive fixed prosthesis [Figure 3].

There is a need for a definitive fixed prosthesis which could be an implant or bridge.

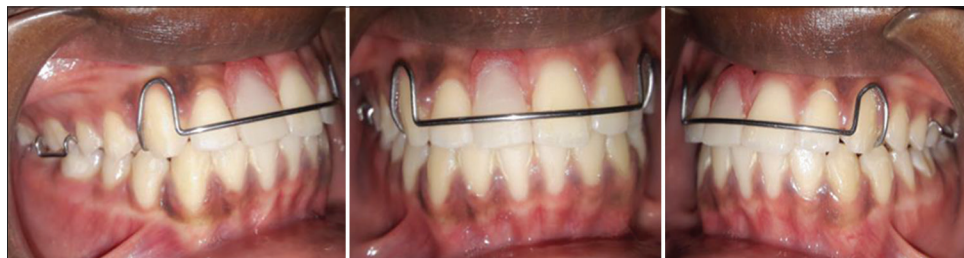

Figure 3: After treatment.

CONCLUSION

Restoration of teeth, especially the anterior teeth, successfully within the esthetical zone results in a clearly positive impact on patient's self-esteem, it improves function, speech and impacts positively on quality of life of an individual.

Declaration of patient consent

The authors certify that they have obtained all appropriate patient consent.

Financial support and sponsorship

Nil.

Conflicts of interest

There are no conflicts of interest.

REFERENCES

- Muhamad AH, Watted N, Abdulgani A. Congenitally missing lateral incisors; orthodontic, restorative and implant approaches. *Int J Dent Oral Health* 2011;2:24-33.
- Wolfart S, Quaas AC, Freiteg S, Kropp P, Gerber D, Kern M. Subjective and objective perception of upper incisors. *J Oral Rehabil* 2006;33:489-95.
- Andersson L, Andreasen JO, Day P, Trope M, Kenny DJ, Lenzi AR, *et al.* Guidelines for the management of traumatic dental injuries: 2. Avulsion of permanent teeth. *Pediatr Dent* 2016;38:369-76.
- Di Angelis AJ, Andreasen JO, Ebeleseder KA, Kenny DJ, Trope M, Lenzi AR, *et al.* Guidelines for the management of traumatic dental injuries: 1. Fractures and luxations of permanent teeth. *Pediatr Dent* 2016;38:358-68.
- Chauhan VS, Chauhan RS, Vibhute ND, More S. Gingival and periodontal diseases in children and adolescents. *J Dent Allied Sci* 2012;1:26-9.
- Haralur SB, Al-Qahtani AS. Replacement of missing anterior teeth in a patient with chronic mouth breathing and tongue thrusting. *Case Rep Dent* 2013;2013:759162.
- Gautam DK, Jindal V, Thakur R. Effect of cigarette smoking on the Periodontal health status: A comparative, cross-sectional study. *J Indian Soc Periodontol* 2011;15:383-7.
- Zee KY. Smoking and periodontal disease. *Aust Dent J* 2009;54:544-50.
- Natarajan P, Madhankumar S, Jeyapalan K, Natarajan S, Kumar VA, Sruthi R. Reasons and associated problems for not replacing lost teeth: A cross sectional survey. *Biomed Pharmacol J* 2018;11:965-9.
- Nayib JF, Marquez RS. Aesthetic approach for post-extraction alveolar socket in the anterior maxilla: Literature review and clinical evaluation. *EC Dent Sci* 2019;18:892-919.
- Cobourne MT, DiBiase AT. *Handbook of Orthodontics*. 1st ed. St Louis: Mosby; 2009.
- Kalia G, Tandon S, Bhupali NR, Rathore A, Mathur R, Rathore K. Speech evaluation in children with missing anterior teeth and after prosthetic rehabilitation with fixed functional space maintainer. *J Indian Soc Pedod Prev Dent* 2018;36:391-5.
- Runte C, Lawerino M, Dirksen D, Bollmann F, Lamprecht-Dinnesen A, Seifert E, *et al.* The influence of maxillary central incisor position in complete dentures on /s/ sound production. *J Prosthet Dent* 2001;85:485-95.
- Goldstein RE. Study of need for esthetics in dentistry. *J Prosthet Dent* 1969;21:589-98.
- Schubert A, Jäger F, Maltha JC, Bartzela TN. Age effect on orthodontic tooth movement rate and the composition of gingival crevicular fluid: A literature review. *J Orofac Orthop* 2020;81:113-25.
- Waeil B, Ibtisam A. Space creation for a missing central incisor using functional and fixed appliance. *J Orthod Sci* 2018;7:8.
- Abu-Hussein M, Watted N, Hegedús V, Peter B. Congenitally missing upper laterals. Clinical considerations: Orthodontic space closure. *J Dent Oral Health* 2015;1:14.
- Rendon J. *Effect of Congenitally Missing Lateral Incisors on the Eruption and Impaction of the Maxillary Canine*. United States: Saint Louis University; 2005.

How to cite this article: Adekoya MN. Adjunctive orthodontic management of a missing upper right central incisor in a 12-year-old male using a fixed orthodontic appliance. *Calabar J Health Sci* 2021;5(1):31-4.